

Peregrine Falcon Admitted to Wildlife Center

**PATIENT:** Peregrine Falcon, [#10-2118](#)

**LOCATION:** Richmond, Virginia

**CAUSE OF ADMISSION:** On ground, unable to fly

**ADMISSION DATE:** October 12

**PROGNOSIS:** Extent of injuries to eye and right shoulder will need to be assessed.



A female Peregrine Falcon is currently undergoing treatment at the Wildlife Center of Virginia.

The Peregrine Falcon was found on the ground, injured and unable to fly, on East Cary Street in Richmond on Tuesday, October 12. She was picked up by A. K. Taylor of Richmond Animal Control and taken to the [Cary Street Animal Hospital](#).

The falcon was examined by Dr. Kimberly Kuhn. Dr. Kuhn took x-rays of the bird and, in consultation with Wildlife Center veterinarian Dr. Miranda Sadar, concluded that the falcon should be brought to the Center in Waynesboro. Volunteer transporter Michael Knight drove the falcon to the Center, arriving at about 9 p.m.

At admission, the falcon was assigned Patient #10-2118 and examined by Dr. Sadar, assisted by Dr. Marc Isidoro Ayza [from Spain] and Pedro Paulo Giese Krindges [a veterinary student from Brazil]. In addition to a coracoid fracture identified in the earlier x-rays, the Center vet team found injuries to the falcon's right shoulder and a detached retina in the bird's right eye. Given that all of the injuries are on the same side of the bird, Center vets surmise that the falcon may have hit the side of a building or some other object.

Center vets administered pain medications, fluids, and anti-inflammatories and secured the falcon in a body wrap.

#### **Photos from October 13 examination**

On October 14, the Center veterinary staff did a blood test on the falcon — results were within normal ranges. The staff redid the body wrap that was used to keep the bird from flapping its injured wing. With the old wrap, the falcon was sternal; with the new wrap, the bird is standing. The falcon was offered “quail two ways” — whole and chopped — and ate [she seemed to prefer whole].

#### **October 18 update**

The peregrine was brought into the clinic for an examination and check-up by Drs. Miranda Sadar and Kelly Flaminio on October 18. New radiographs were taken, which indicated that the injuries to the right shoulder are healing well. The fractured portion of the coracoid is well-positioned. The vets will likely need to keep the peregrine in a body wrap for another two to three weeks.

The vet staff also had the first opportunity to perform a more thorough examination of the

The  
**Wildlife Center**  
OF VIRGINIA

[about WCV](#)

[news & events](#)

[environmental education](#)

[veterinary training](#)

[rehabilitator training](#)

[information technology](#)

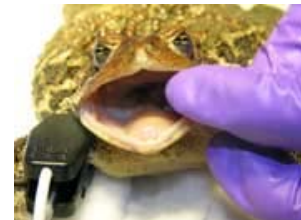[wildlife disease surveillance](#)

[support the center](#)

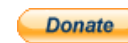[WCV home](#)

***I NEED RESCUE ADVICE!***

***Virginia Wildlife Health  
Information Resource***



[+] enlarge



peregrine's eyes while she was under anesthesia. Upon admission, the Center vets found that the peregrine had a detached retina in her right eye. On October 18, the vets found no improvement in that eye. In addition, a small spot was found in the peregrine's left eye — most likely an older eye injury.

### October 21 update


---

On October 21, Drs. Miranda and Kelly took the peregrine to the Virginia-Maryland Regional College of Veterinary Medicine at Virginia Tech for a consultation with [J. Phillip Pickett](#), DVM, Professor of Ophthalmology in the Department of Small Animal Clinical Sciences and Diplomate, American College of Veterinary Ophthalmologists.

Dr. Pickett and his team found encouraging signs of healing in the bird's right eye, with reattachment of the retina. Dr. Pickett also examined the bird's left eye. There are two small scars there, which do not appear to compromise the bird's sight.

Dr. Pickett would like to examine the peregrine in another four to five weeks [November 18 or later] to see how the eye has healed and to check the falcon's sight.

Patient #10-2118 will continue to be housed in the Center's inside patient ward, in a body wrap, for another two to three weeks. She is eating well — “like a pig”, to quote Dr. Miranda.



*Photos from the examination: Drs. Pickett and Flaminio [left photo] and Senior Veterinary Student Cassie Fox [right photo]*

### October 25 Update: A Case of Mistaken Identity ...

---

The falcon — a large female [weight of 1 kg] — was initially identified by Virginia Department of Game and Inland Fisheries biologists as the female from the pair of peregrines that have been nesting in downtown Richmond since 2003 — first at the BBT Building, and more recently on the west building of the Riverfront Plaza. This pair has produced numerous offspring, included chicks that have been used to introduce peregrines into other areas of Virginia. This female also had been the “star” of the [VDGIF Falcon Cam](#) — a web-based camera focused on the falcon's nest. Web-cam watchers have given this bird the name “Harriet” — her mate, of course, is Ozzie.

However, VDGIF biologists have now changed their minds and have concluded that #10-2118 is NOT “Harriet”. A pair of peregrine falcons has been seen in the past few days defending the downtown Richmond nesting site, and careful examination of photos of Harriet and #10-2118 suggest that these are NOT the same birds.

**So who is #10-2118?** According to Dr. Dave McRuer, the Center's Director of Veterinary Services, this adult female is likely a southbound migrant — most probably from New England, Canada, or even Greenland.

The Peregrine Falcon is a native species to Virginia, once nesting in the Allegheny and Blue Ridge Mountains. By the early 1960s, the falcon was believed to be extinct as a breeding species in Virginia and all areas east of the Mississippi River — a decline linked to the widespread use of DDT and other chemicals. A program of peregrine reintroduction began in Virginia in 1978. There are now about 20 known breeding pairs of peregrines in Virginia.

[Additional information on December 2009 Peregrine Falcon release](#)

[The Wildlife Center depends on the donations of caring individuals for the health care provided to this Peregrine Falcon – and to about 2,500 wild animals in need each year. Please help!](#)

**News Stories about Peregrine:**

October 23, 2010

[Falcon Injured in Downtown Richmond Appears to Improve](#), Richmond Times-Dispatch

October 16, 2010

[Famous Birds in the Care of Wildlife Center of Virginia](#), WHSV-TV

October 15, 2010

[Rare Richmond Peregrine Falcon Injured](#), Richmond Times-Dispatch

October 14, 2010

[Wildlife Center Treating “Celebrity” Birds](#), WVIR-TV

**October 13, 2010**

[Injured Peregrine Falcon Under Care of Wildlife Center of Virginia](#), WVEC-TV

---

---

---

[news & events](#)  
[international conservation](#)

[veterinary](#)  
[conservation](#)

[education](#)  
[wildlife](#)

[professional training](#)  
[disease surveillance](#)

[public policy / research](#)  
[rehabilitation conference](#)

[support the center](#)  
[information technology](#)

[donor privacy policy](#)  
[rescue advice](#)

P.O. Box 1557, Waynesboro VA 22980 (540) 942-9453  
After-hours wildlife emergency: (540) 241-4045

©2004-2010 The Wildlife Center of Virginia All Rights Reserved  
site programming ©2004-2010 grep Innovation LLC